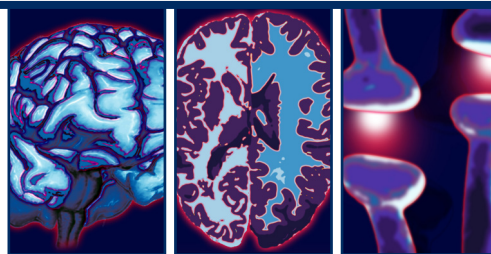


REVIEW

For reprint orders, please contact: reprints@futuremedicine.com



Body dysmorphic disorder: a review of nosology, cognition and neurobiology

Ben G Buchanan¹, Susan L Rossell² & David J Castle[†]

Practice points

- Body dysmorphic disorder (BDD) is underdiagnosed, as individuals with BDD are unlikely to reveal their body image concerns unless directly asked. They may, however, seek cosmetic procedures for their perceived defect or psychological treatment for a comorbid condition.
- Common comorbid conditions include depression, social phobia, anorexia nervosa and obsessive–compulsive disorder.
- Obsessive–compulsive disorder and BDD have similar symptoms and research is beginning to show that they also have similar underlying cognitive dysfunctions.
- The delusional subtype of BDD is best considered as a more severe case of BDD with lower levels of insight, rather than a separate subtype.
- Individuals with BDD have visual processing abnormalities including a tendency to process visual information in a piecemeal manner rather than holistically. This indicates that they see things differently and may explain their fixations on slight anomalies in their own appearance.
- Hyperactivity in the limbic system may explain why individuals with BDD feel that they are constantly being negatively judged by others.
- BDD can be successfully treated with cognitive behavioral therapy and medication.

SUMMARY An understanding of the neurocognitive and neurobiological underpinnings of body dysmorphic disorder (BDD) is important in differentiating BDD from related disorders, namely obsessive–compulsive disorder and psychotic disorders. Similar cognitive anomalies in executive function, spatial visual processing and memory (bias to process detailed visual information) have been found in BDD and obsessive–compulsive disorder samples, while schizophrenia patients display more pervasive cognitive deficits. Emotional hyperactivity

¹School of Psychology & Psychiatry, Faculty of Medicine, Nursing & Health Sciences, Monash University, Monash Alfred Psychiatry Research Centre, 1st Floor, Old Baker Building, The Alfred Hospital, Commercial Road, Melbourne, VIC 3004, Australia

²School of Psychology & Psychiatry, Faculty of Medicine, Nursing & Health Sciences, Monash University & Brain Sciences Institute, Faculty of Life & Social Sciences, Swinburne University, Cognitive Neuropsychology Laboratory, Monash Alfred Psychiatry Research Centre, 1st Floor, Old Baker Building, The Alfred Hospital, Commercial Road, Melbourne, VIC 3004, Australia

[†]Author for correspondence: St Vincent's Hospital & the University of Melbourne, Level 2, 46 Nicholson Street, PO Box 2900, Fitzroy, VIC 3065, Australia;

Tel: +61 392 884 751; Fax: +61 392 884 802; david.castle@svhm.org.au

and misinterpretation of emotion in others have been found in BDD, with similar results to obsessive-compulsive disorder samples. Neuroimaging has shown abnormalities in the prefrontal cortex, visual cortex, caudate nucleus and right amygdala in BDD patients. These findings are consistent with the neurocognitive profile. This field of research is in its infancy. However, the bias towards detailed visual analysis may be an important clue when investigating the neurobiological basis of BDD, and could explain why individuals exhibit focused attention on one aspect of their own appearance. Emotional hyperarousal caused by amygdala pathology may reinforce a perception of negative physical appearance.

A degree of concern regarding physical appearance is culturally accepted and even expected; however, for some individuals concern regarding their appearance is excessive and causes them considerable distress. These people may be identified as having body dysmorphic disorder (BDD), which is a mental disorder that includes obsessive-compulsive phenomena and overvalued ideas that may become delusional. This article will discuss the phenomenological similarities between BDD, obsessive-compulsive disorder (OCD) and psychotic disorders and review neuropsychological and brain imaging studies and their possible implications for a neurobiological model of BDD.

Characteristics of BDD

Individuals with BDD frequently describe themselves as unattractive, disfigured, deformed or ugly and are preoccupied with one or more aspect of their appearance that they attest to looking abnormal. The disorder's essential feature, as defined by the Diagnostic and Statistical Manual of Mental Disorders, Fourth Edition, Text Revised (DSM-IV-TR) [1], is a preoccupation with some imagined defect in appearance, or, if a slight physical abnormality is present, that the person has a disproportionate concern regarding the anomaly. Furthermore, individuals with BDD often demonstrate little insight into the fact that their self-perception of repulsiveness is unrealistic, and these beliefs may thus reach delusional proportions.

Body dysmorphic disorder patients are usually preoccupied with their face or head, and most commonly their skin, hair or nose [2]; they can spend between 3 and 8 h per day thinking about their perceived defects; in fact some individuals report that these thoughts are present continuously [3]. Beliefs about their defects usually carry strong personal meaning, and are often cited as the main reason for personal problems [4], for example, "I cannot get a job because of my nose". Many individuals with BDD give almost exclusive attention to their perceived flaws while ignoring other aspects of their appearance.

Individuals with BDD have impaired psychosocial functioning and quality of life [5]. They may experience prolonged unemployment, severe social isolation and suicidal ideation, with approximately 25% of individuals with BDD attempting suicide [6].

Prevalence rates of BDD are reportedly between 0.7 [7] and 2.4% [8], with similar levels in males and females. It is generally underdiagnosed, as individuals are not likely to reveal their symptoms unless directly questioned about their body image concerns. The secretive nature of BDD, as well as the strongly held belief that they possess a physical defect rather than a psychological problem, means that few individuals with BDD will seek appropriate treatment. They may, however, opt for cosmetic procedures to 'cure' their problem. For example, Veale *et al.* found in their BDD samples that 26% had had one or more cosmetic operations [3]. Furthermore, the vast majority (83% in the study by Phillips *et al.* [9]) of BDD patients experience either no improvement or a worsening of BDD symptoms after surgery. In cosmetic settings, rates of BDD are high: 7% in a sample of cosmetic surgery patients [10] and between 8.8 and 14% in dermatology patients [11,12]. If individuals with BDD do present for psychological treatment it is often for a secondary or associated condition, such as depression, OCD, anorexia nervosa or social anxiety [13–15]. Patients are commonly not diagnosed with BDD until 10–15 years after the onset, which usually occurs in adolescence [16]. The course of the disorder is generally chronic if untreated. If treated with psychological therapy and medication [17], however, the outlook is more optimistic, with nearly 60% achieving remission after 4 years.

Nosology

At present BDD is classified as a somatoform disorder in the DSM-IV-TR. However, it is widely acknowledged that the nosological status of BDD is in need of review [18,19], with the DSM-V Working Group recommending that BDD be reclassified as either an anxiety disorder or an

obsessive–compulsive spectrum disorder [19,101]. There is also debate relating to the delusional subtype of BDD, and how this can best be conceptualized within the BDD classification framework. Currently the delusional variant requires a separate, additional, classification with the delusional disorders.

There is also debate over how BDD relates to other mental disorders. For example, social phobia shares many characteristics with BDD, such as the tendency to feel socially anxious and chronic fear of embarrassment or rejection [20]. In fact, 39% of individuals with BDD have had comorbid lifetime social phobia [20]. While BDD has been compared with many disorders, this article will focus on the issues most salient in the context of the possible reclassification of the disorder within the DSM-V, namely BDD as an obsessive–compulsive spectrum disorder and BDD's delusional variant.

■ BDD as an obsessive–compulsive spectrum disorder

Body dysmorphic disorder shows several similarities to OCD, including:

- Preoccupations that are often described as obsessional, anxiety producing and difficult to control [21];
- Engagement in repetitive and ritualistic behaviors, such as skin picking and checking behaviors, which may take up many hours of the day [22];
- A concern with esthetics such as symmetry [23];
- A tendency to engage in reassurance seeking from others [23];
- Social withdrawal [24].

A number of studies have directly compared BDD to OCD on a broad range of demographic and clinical features, with relatively consistent findings [14,24–26]. Comorbidity studies have tended to focus on the prevalence of BDD in OCD samples. They have shown that 7.7–15.3% of those with OCD meet diagnostic criteria for concurrent BDD [15,23]. The high comorbidity rate may represent a diagnostic overlap or an etiological link. In clinical BDD samples, OCD is a frequent comorbid disorder (41%) [27]. Furthermore, familial studies have demonstrated a familial link between OCD and BDD. Hollander, Cohen and Simeon found that OCD

was the most common disorder found in the relatives of 50 BDD participants, with 17% of them having first-degree relatives with OCD [28].

As well as the phenomenological and familial links between OCD and BDD, both disorders have similar treatment responses to serotonergic reuptake inhibitor medications [29,30]. Given these similarities there seems to be a general consensus towards conceptualizing BDD as an obsessive–compulsive spectrum disorder [31], and some neuropsychological studies have set out to measure BDD against OCD to test this conceptualization; this is addressed below.

■ Delusional & nondelusional subtype

A key difference between OCD and BDD, and a topic of debate regarding subtypes of BDD, is the delusional and nondelusional typology. In BDD, obsessions tend to be held with more conviction and less insight than those of OCD [32]. Thus, whilst only 2% of OCD patients were 'delusional', 27% of BDD participants were currently delusional according to the Brown Assessment of Beliefs Scale. Other studies have found a higher rate of delusions in BDD, of between 34 and 60% [33,34]. In contrast to delusions in psychotic disorders such as schizophrenia, delusional beliefs in BDD tend to be nonbizarre and monothematic and generally linked to their perceived flaw. BDD patients also often experience delusions of reference, such as the belief that other people take special notice of the supposed defect, for example, talk about it and mock it [35].

Under the present diagnostic system for BDD in the DSM-IV-TR there is the provision of a secondary diagnosis of a delusional disorder within the delusional disorder group, somatic subtype. This diagnosis is given if beliefs reach delusional intensity, or strong ideas of reference are present. The current psychotic/nonpsychotic dichotomy has been under scrutiny because the separate classification of the types implies that they are, in fact, distinct disorders. However, available evidence suggests that the delusions present in BDD should not be represented as a categorical difference in classification but rather reflect a dimensional intensity of belief [34,36]. To this end, there has been considerable speculation regarding a dimensional approach to the delusional aspect of BDD in development of the DSM-V [18,34,37].

Nevertheless, there are several differences between the subtypes: individuals with delusional BDD experience more impairment in social functioning, more suicide attempts and

rate of hospitalization, and have more severe BDD symptoms compared with their non-delusional counterparts [33,38]. Delusional subjects also have lower scores on nearly all functioning and quality of life variables. However, there are more similarities than differences between the two subtypes, including age, comorbidity and, most importantly, the core symptomatology of BDD. Moreover, both delusional and nondelusional variants respond similarly to serotonin reuptake inhibitor pharmacotherapy [39]. Thus, the delusional subtype patients could merely have a more severe form of the same core disorder.

Neurocognition

The severe body image distortions that individuals with BDD experience suggest that fundamental cognitive and perceptual abnormalities are involved. Cognitive research has revealed a range of deficits in BDD, including executive function [40,41], selective attention [42], information processing [41,43], recognition of emotion in others [44] and visual processing [45,46].

In the context of the nosological debate surrounding BDD, studies that have directly compared cognition in BDD, OCD and schizophrenia are of particular interest. Hanes compared a BDD group with OCD and schizophrenia groups on executive function tasks [40]. Parallel deficits in BDD and OCD were found, while the schizophrenia group showed more severe and widespread deficits. The author concluded that the cognitive similarities between OCD and BDD imply that the neuroanatomical underpinnings may be similar. In OCD, impairment on one of the same executive function tasks (Stroop color naming) has been shown to be associated with abnormal frontal–striatal and limbic activation [47], although this has not, to our knowledge, been directly investigated in BDD.

Dunai *et al.* demonstrated executive function impairments in BDD patients compared with nonclinical controls, with the BDD group making more errors on a Spatial Working Memory task, and performing more slowly on the Stocking of Cambridge task, which required organization, planning and online manipulation of visual information [41]. Such deficits, on the same tasks, have previously been observed in OCD [48] and schizophrenia [49]. Executive function deficits in BDD, however, were not pervasive, and the BDD group scored similarly to controls on a pattern recognition task and another

test of spatial short-term memory, suggesting that spatial memory capacity, motor speed and visual memory are intact.

One of the most cited neuropsychological findings in BDD has been that individuals with BDD process images in a detailed fashion rather than in a more holistic way [43,50]. Deckerbach *et al.* demonstrated disruptions in visual learning when holistic organization of visual information is required rather than detailed analysis [43]; this is also characteristic of OCD [51,52]. Interestingly, holistic visual processing disruption with facial stimuli was shown in schizophrenia by Joshua and Rossell [53], suggesting that BDD, OCD and schizophrenia all have a bias towards detailed visual processing. However, no published studies have directly compared BDD with OCD or schizophrenia in this regard, so any conclusions are only tentative.

In a recent study examining detail bias in BDD [50], participants viewed images of faces that were either upright or inverted. Inverted faces slowed the recognition response time in both BDD and control groups, but individuals with BDD slowed significantly less than controls. Gestalt recognition is disrupted when images are inverted and the smaller response delay for the BDD group suggests they rely on detailed visual analysis, causing less disruption when images are inverted. This detailed analysis bias has also been demonstrated in a study that showed that individuals with BDD were more accurate than controls with dermatological conditions at noticing small differences between facial images [54]. However, there has been some variation in results, with BDD participants in another study showing no difference to OCD and control subjects in their ability to detect slight asymmetry in faces [55].

Other studies of BDD patients have focused on facial emotional recognition. One study compared BDD with OCD on a facial emotion identification task [44] and found that both disorders were associated with difficulties interpreting the emotional facial expressions compared with controls. The BDD group more often misidentified emotional expressions as angry compared with OCD and control subjects. Such emotional misinterpretation has also been shown for nonface general social scenarios [56,57], suggesting a more generalized emotional hyperarousal. In another study requiring matching of faces [58], BDD participants performed similarly to nonclinical controls when the stimulus facial expression was neutral. However, when the stimulus faces were

showing emotion (e.g., sad, happy or angry), BDD participants reacted more slowly and made twice as many mistakes as controls, indicating a tendency to be distracted by emotional cues and a possible hypersensitivity to emotion.

Identification of these emotional biases, coupled with fundamental cognitive abnormalities and deficits in information processing can inform our understanding of the neurobiological abnormalities underpinning BDD. Thus, this review of neurocognition illustrates that individuals with BDD have abnormal ways of processing information and these may be linked to specific brain regions. For example, poor executive functioning is surmised to be a result of abnormalities in the prefrontal cortex [40,41], while memory deficits are thought to involve abnormalities of the medial temporal cortex [43]; and poor facial expression recognition implicates underlying networks involved in facial recognition, including the superior temporal sulcus [59]. More specifically, interpretation biases may implicate an emotional regulation system in the brain, particularly the limbic system [60]. Specific functional neuroimaging experiments will need to be conducted to confirm these interpretations, but there is a coherent emerging story that can now be told. We now turn to neuroimaging studies that have investigated the pathophysiology of BDD. None of these studies have directly compared BDD with other disorders.

Neuroimaging

Both functional and structural imaging has been conducted with BDD patients. Functional imaging has tended to focus on activation levels while the participants engage in visual processing tasks, as their symptomatology is closely related to these systems.

Feusner *et al.* conducted an functional MRI (fMRI) study to explore brain activation in 13 BDD and 12 control participants [46]. The participants were presented with faces that had been digitally manipulated to either have low, normal or high levels of detail. The low spatial frequency was blurred, while the high spatial frequency had exaggerated contour details. Previous research has shown that visual processing of detailed stimuli produces different brain activation to global processing in healthy participants [61,62]. Given that individuals with BDD tend to have a bias toward detail in visual analysis [43,50], patterns of brain activation in

response to the three different spatial frequency stimuli were expected to be different to controls. The researchers found two major group differences. First, right amygdala activation was significantly greater in the BDD group for high spatial frequency and low spatial frequency facial pictures, but there were similar levels of activation for the normal resolution pictures. Second, there was more left hemispheric activation in the lateral aspects of the middle and inferior prefrontal cortex in the high and low spatial frequency face presentation for the BDD group, while controls had more right activation. Studies with healthy individuals have demonstrated that left prefrontal cortex activation is associated with local or analytical processing, while the right prefrontal cortex has increased activation for holistic or global processing [63]. The results from this study showing greater activation in the BDD group for brain regions associated with detailed analysis, taken together with the Deckersbach *et al.* study showing a bias for detailed visual information organization, suggest that BDD participants engage in a more piecemeal and detailed analysis of faces compared with healthy individuals [43].

A subsequent study with a similar design aimed to examine brain function particular to visual presentation of BDD participants' own face or a familiar face [64]. The BDD patients ($n = 17$) demonstrated lower levels of activation in primary and secondary visual cortical areas for low-detail images for their own faces and faces of familiar people, compared with 16 healthy controls. Since the low-detail images require holistic processing, abnormal brain activation may indicate difficulties in processing such information. In addition, this study demonstrated hyperactivity in the left orbitofrontal cortex and bilateral caudate when shown a picture of their unaltered face, compared with the familiar face condition. OCD samples have also demonstrated hyperactivity in these areas [65], supporting their conceptual association. The study also found that frontostriatal activation was correlated with higher levels of obsessive thoughts and compulsive behaviors in the BDD group. These two studies are particularly interesting because the face is the most common area of fixation in BDD. Future research should consider comparing BDD groups based on the area of fixation (facial vs body), as cortical differences may be present. Abnormal cortical activation in BDD patients has also been found for

visual stimuli, which is unrelated to BDD symptoms. Feusner *et al.* found that, when presented with manipulated images of houses, individuals with BDD showed similar abnormalities in brain activation as when shown faces [66]. This suggests general abnormalities in visual processing rather than symptom-specific deficits.

Another brain imaging study used single photon emission computed tomography with six BDD participants [67]. Single photon emission computed tomography imaging uses injected radioactive material to measure blood flow (perfusion) in different areas of the brain. There was no control group in this study, thus the results from brain regions of interest were compared with previously acquired and standardized region-of-interest templates. The study found widespread neurocircuitry abnormalities, including perfusion deficits in bilateral anterior–medial temporal and occipital regions and frontal areas, and asymmetrical perfusion in parietal lobes. Of particular note were the blood flow deficits in the temporal regions, as these regions are associated with body image perception [68]. Ventral areas of the temporal region are known to be involved in face perception, while anterior areas are involved in visual processing [59,69]; both functions have been shown to be abnormal in BDD [43,70]. However, owing to the small sample size and no control group, replications of these findings are needed.

Neuroanatomical differences in BDD were studied by Rauch and colleagues [71]. They conducted a brain structure study using morphometric MRI with eight female BDD participants and the same number of sex-matched controls. They reasoned that studying brain structure could establish a basis for comparison of BDD to other obsessive–compulsive spectrum disorders. Their results showed that there was greater total white matter volume and a left-shifted caudate asymmetry in BDD. These results may explain the selective attentional biases towards detail found in the cognitive studies reviewed previously [43,50,58], as the caudate region is involved in the filtering of new sensory information, learning and memory. The caudate nucleus is also consistently abnormal in OCD samples [72]. Volumetric differences between all other measured brain regions, including the amygdala, thalamas, globus pallidus, hippocampus and putamen, were not significant. However, owing to the female gender bias in the sample and the small sample size, these results should be

viewed with caution, as nonsignificant findings may be due to a lack of power and significant findings may be due to sampling error.

In contrast to the all-female sample in the above study, Atmaca *et al.* compared 12 male BDD subjects who were unmedicated with 12 male controls [73]. Greater total white matter volumes were found, confirming the results of Rauch *et al.* [71]. Consistent with fMRI data showing hyperactivity in the orbitofrontal cortex [64], this structural study found that the BDD group had significantly smaller orbitofrontal cortices compared with controls. Furthermore, the study found that the longer the duration of illness the smaller the orbitofrontal cortex volumes, suggesting hypotrophy caused by hyperactivation. These results may explain the executive function and emotional regulation deficits in BDD. In addition, these results give further support for the conceptual link between OCD and BDD, as similar reductions in volumes have been demonstrated in the orbitofrontal cortex in OCD [74,75].

Feusner and colleagues also undertook a structural imaging study with 12 BDD participants and 12 controls [76]. This study measured specific regions of interest using a manual tracing technique, limiting the brain regions measured to the amygdale, caudate and inferior frontal gyri. This technique is in contrast to the Rauch *et al.* study, which measured more regions with a more automated, although less accurate, process [77], making comparison between their studies difficult. Feusner *et al.* [76] found no significant differences between the groups in terms of volumetric differences in white and gray matter or their regions of interest. However, symptom severity within the BDD group was significantly positively correlated with right amygdala volumes, supporting previous fMRI data of abnormal right amygdala activation [46]. This finding is consistent with current knowledge on amygdala function, as the amygdalae have consistently been shown to be involved with emotional arousal [78] and affective facial recognition [60]. The right amygdala is particularly active in tasks that require the processing of emotional visual information [61]. As individuals with BDD have been shown to have high emotional arousal, biases in affective facial recognition tasks [70] and their primary symptoms involve visual emotional disturbances, the finding of right amygdala structural and functional abnormalities suggests that hyperactive amygdalae might be important in BDD

symptomatology. However, further evidence of amygdala pathology is needed, especially as the Fuesner *et al.* structural study [76] again had a small sample size. In fact, the reported significant correlation between amygdala size and symptom severity may be explained by two outliers among the 12 data points.

Figure 1 shows brain areas that have been shown to be abnormal in BDD. In addition, in terms of general differences between BDD and control brains, increased white matter volumes and leftward shift in hemispheric activation have been consistent findings.

The etiology of BDD

This article has focused on neurocognitive and neurobiological underpinnings of BDD, but these can by no means comprehensively explain the mechanisms by which BDD evolves within certain individuals. For example, certain psychological and sociocultural factors have been shown to be related to the onset of BDD [79,80]: the causal interaction of these factors has been conceptualized well in the cognitive behavioral model of BDD [80,81]. However, neurobiological pathology, as discussed here, represent the most direct factors underlying BDD symptomatology. Such pathology is perhaps influenced by genetic factors and early environmental experiences. Indeed, genetic influences have been shown to be important, with

prevalence studies showing higher BDD rates of 5.8–8% among first-degree relatives of those with BDD [5,82]; there is also a genetic link to OCD [28]. Thus, any holistic model of BDD must encompass all of these parameters.

Conclusion

While much is known regarding the phenomenology of BDD, further research is needed into the fundamental cognitive and neurophysiological underpinnings of the disorder. Neuropsychological studies have indirectly implicated certain regions of the brain and contributed to the formulation of a neurobiological paradigm of BDD. Based on this evidence, it is possible that the perceptual distortions experienced by individuals with BDD are caused by a tendency to process detailed visual information rather than configural arrangement. Neuroimaging research to date supports this, showing hyperactivity in the left hemisphere associated with detailed analysis, rather than the right hemisphere-mediated holistic appraisal. The tendency for individuals with BDD to mirror gaze and focus on one aspect of their appearance can be explained through this mechanism. The emotional hyperactivity and misinterpretations experienced in BDD may make individuals with the disorder more likely to interpret slight physical anomalies in a

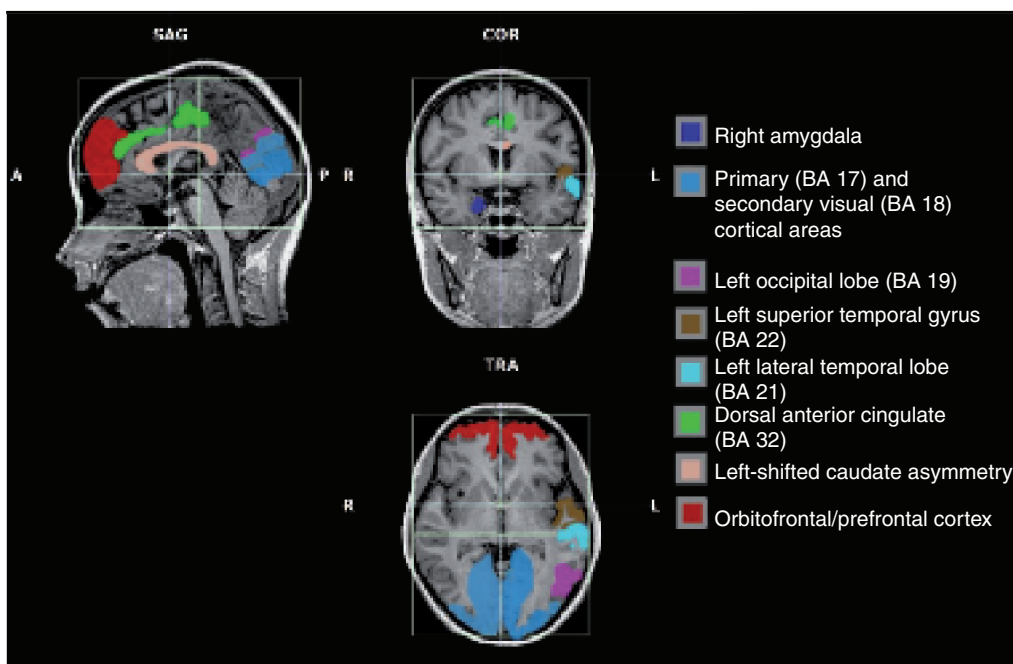


Figure 1. Implicated brain regions in body dysmorphic disorder.

negative manner, exaggerated by the perceived negative evaluation by others. This may involve abnormal functioning of the limbic system including the amygdalae.

In terms of the nosological debate around BDD as an OCD or a delusional disorder, the available data have produced more support for BDD's conceptualization as an obsessive–compulsive spectrum disorder. Similarities to OCD in executive function, visual processing, facial emotion recognition and abnormal patterns of activation in the orbitofrontal cortex have been found. These similarities, however, are largely based on comparison of separate study's findings. Beyond neurocognitive similarities, OCD and BDD still have an important difference in terms of insight, and the delusions present in BDD make classification within an obsessive–compulsive spectrum disorder category problematic. Thus, more data directly comparing BDD with OCD and schizophrenia are needed. Neurocognitive similarities between BDD and schizophrenia should also be directly examined, as comparative neuroimaging studies would help inform the nosological debate.

Future perspective

Over the next decade it is predicted that there will be greater emphasis on untangling the etiological factors important for understanding

BDD. This will include an influx of neuroimaging studies examining the integrity of both the structure and function of the brain using MRI and other techniques. There is also scope to employ other technologies, including advanced modern eye tracking. Eye movement abnormalities have frequently been reported in other mental illnesses, including schizophrenia and other anxiety disorders. There is a particular dearth of such investigation in BDD, which is surprising given the extensive literature on visual processing problems.

In addition, the publication of the DSM-V may see BDD placed as an obsessive–compulsive spectrum disorder. However, there will be ongoing debate as to the significance of delusions in BDD and the nosological implications thereof.

Financial & competing interests disclosure

The authors have no relevant affiliations or financial involvement with any organization or entity with a financial interest in or financial conflict with the subject matter or materials discussed in the manuscript. This includes employment, consultancies, honoraria, stock ownership or options, expert testimony, grants or patents received or pending, or royalties.

No writing assistance was utilized in the production of this manuscript.

Bibliography

Papers of special note have been highlighted as:
■ of interest

- 1 American Psychiatric Association: *Diagnostic and Statistical Manual of Mental Disorders. 4th Edition, Text Revision*. American Psychiatric Association, Washington, DC, USA (2000).
- 2 Neziroglu F: Body dysmorphic disorder: causes, characteristics, and clinical treatments. *Body Image* 5(1), 1–2 (2008).
- 3 Veale D, Boocock A, Gournay K *et al.*: Body dysmorphic disorder: a survey of 50 cases. *Br. J. Psychiatry* 169, 196–201 (1996).
- 4 Veale D: Body dysmorphic disorder *Postgrad. Med. J.* 80, 67–71 (2003).
- 5 Phillips K, Menard W, Fay C, Weisberg R: Demographic characteristics, phenomenology, comorbidity, and family history in 200 individuals with body dysmorphic disorder. *Psychosomatics* 46(4), 317–325 (2005).
- 6 Phillips K, Coles ME, Menard W, Yen S, Fay C, Weisberg RB: Suicidal ideation and suicide attempts in body dysmorphic disorder. *J. Clin. Psychiatry* 66, 717–722 (2005).
- 7 Otto MW, Wilhelm S, Cohen LS, Harlow BL: Prevalence of body dysmorphic disorder in a community sample of women. *Am. J. Psychiatry* 158, 2061–2063 (2001).
- 8 Koran L, Aboujaoude E, Large M, Serpe R: The prevalence of body dysmorphic disorder in the United States adult population. *CNS Spectrums* 13(4), 316–322 (2008).
- 9 Phillips K, Grant J, Siniscalchi J, Albertini R: Surgical and nonpsychiatric medical treatment of patients with body dysmorphic disorder. *Psychosomatics* 42(6), 504–510 (2001).
- 10 Sarwer D, Wadden T, Pertschuk M, Whitaker L: Body image dissatisfaction and body dysmorphic disorder in 100 cosmetic surgery patients. *Plast. Reconstr. Surg.* 101(6), 1644–1649 (1998).
- 11 Conrado L, Hounie A, Diniz J *et al.*: Body dysmorphic disorder among dermatologic patients: prevalence and clinical features. *J. Am. Acad. Dermatol.* 63(2), 235–243 (2010).
- 12 Phillips K, Dufresne R Jr, Wilkel C, Vittorio C: Rate of body dysmorphic disorder in dermatology patients. *J. Am. Acad. Dermatol.* 42(3), 436 (2000).
- 13 Nierenberg A, Phillips K, Petersen T *et al.*: Body dysmorphic disorder in outpatients with major depression. *J. Affect. Disord.* 69(1–3), 141–148 (2002).
- 14 Simeon D, Hollander E, Stein DJ *et al.*: Body dysmorphic disorder in the DSM-IV field trial for obsessive–compulsive disorder. *Am. J. Psychiatry* 152(8), 1207–1209 (1995).
- 15 Wilhelm S, Otto MW, Zucker BG, Pollack MH: Prevalence of body dysmorphic disorder in patients with anxiety disorders. *J. Anxiety Disord.* 11(5), 499–502 (1997).

- 16 Veale D: Body dysmorphic disorder. In: *Oxford Handbook of Anxiety and Related Disorders*. Antony MM, Stein MB (Eds). Oxford University Press, NY, USA, 541–550 (2009).
- 17 Phillips K, Grant JE, Siniscalchi JM, Stout R, Price LH: A retrospective follow-up study of body dysmorphic disorder. *Compr. Psychiatry* 46, 315–321 (2005).
- 18 Castle D, Russell S, Kyrios M: Body dysmorphic disorder. *Psychiatr. Clin. North Am.* 29, 521–538 (2006).
- 19 Phillips K, Wilhelm S, Koran L *et al.*: Body dysmorphic disorder: some key issues for DSM-V. *Depress. Anxiety* 27(6), 573–591 (2010).
- Examines the possible reclassification of body dysmorphic disorder (BDD) within the Diagnostic and Statistical Manual of Mental Disorders 4th Edition, and specifically reviews the implications of the proposed revised criteria. This review also argues that there is no evidence for the current system of classification with the somatoform disorders, and compares BDD to related disorders.
- 20 Stark R, Schienle A, Walter B *et al.*: Hemodynamic responses to fear and disgust-inducing pictures: an fMRI study. *Int. J. Psychophysiol.* 50(3), 225–234 (2003).
- 21 Hollander E, Phillips K: Body image and experience of disorders. In: *Obsessive–Compulsive–Related Disorders*. Hollander E (Ed.). American Psychiatric Press, Washington, DC, USA, 17–48 (1992).
- 22 Eisen JL, Phillips K, Coles ME, Rasmussen SA: Insight in obsessive–compulsive disorder and body dysmorphic disorder. *Compr. Psychiatry* 45, 10–15 (2004).
- 23 Stewart S, Stack DE, Wilhelm S: Severe obsessive–compulsive disorder with and without body dysmorphic disorder: clinical correlates and implications. *Ann. Clin. Psychiatry* 20(1), 33–38 (2008).
- 24 Frare F, Perugi G, Ruffolo G, Toni C: Obsessive–compulsive disorder and body dysmorphic disorder: a comparison of clinical features. *Eur. Psychiatry* 19(5), 292–298 (2004).
- 25 Phillips K, Gunderson C, Mallya G, McElroy S, Carter W: A comparison study of body dysmorphic disorder and obsessive–compulsive disorder. *J. Clin. Psychiatry* 59, 568–575 (1998).
- 26 Phillips K, Pinto A, Menard W, Eisen JL, Mancebo M, Rasmussen SA: Obsessive–compulsive disorder versus body dysmorphic disorder: a comparison study of two possibly related disorders. *Depress. Anxiety* 24, 399–409 (2007).
- 27 Perugi G, Giannotti D, Frare F *et al.*: Prevalence, phenomenology and comorbidity of body dysmorphic disorder (dysmorphophobia) in a clinical population. *Int. J. Psychiatry Clin. Pract.* 1(2), 77–82 (1997).
- 28 Hollander E, Cohen LS, Simeon D: Body dysmorphic disorder. *Psych. Ann.* 23, 359–364 (1993).
- 29 Landeros-Weisenberger A, Bloch M, Kelmendi B *et al.*: Dimensional predictors of response to SRI pharmacotherapy in obsessive–compulsive disorder. *J. Affect. Disord.* 121(1–2), 175–179 (2010).
- 30 Ipser JC, Sander C, Stein DJ: Pharmacotherapy and psychotherapy for body dysmorphic disorder. *Cochrane Database Syst. Rev.* 1, CD005332 (2009).
- Reviews current literature on effective treatments for BDD, both pharmacotherapy and psychotherapy. The results from the small number of randomized controlled trials indicate that cognitive behavioral therapy and serotonin reuptake inhibitors may be useful in treating patients with BDD.
- 31 Phillips K: Body dysmorphic disorder: diagnostic controversies and treatment challenges. *Bull. Menninger Clin.* 64(1), 18 (2000).
- 32 Vitiello B, De Leon J: Dysmorphophobia misdiagnosed as obsessive–compulsive disorder. *Psychosomatics* 31(2), 220–222 (1990).
- 33 Mancuso S, Knoesen N, Castle D: Delusional versus nondelusional body dysmorphic disorder. *Compr. Psychiatry* 51(2), 177–182 (2010).
- 34 Labuschagne I, Castle DJ, Dunai J, Kyrios M, Russell SL: An examination of delusional thinking and cognitive styles in body dysmorphic disorder. *Aust. NZ J. Psychiatry* 44(8), 706–712 (2010).
- 35 Phillips K, McElroy SL, Keck PE, Pope HG, Hudson JI: Body dysmorphic disorder: 30 cases of imagined ugliness. *Am. J. Psychiatry* 150(2), 302–308 (1993).
- 36 Phillips K, McElroy SL, Keck PE *et al.*: A comparison of delusional and nondelusional body dysmorphic disorder in 100 cases. *Psychopharmacol. Bull.* 30, 179–186 (1994).
- 37 Castle D, Russell S: An update on body dysmorphic disorder. *Curr. Opin. Psychiatry* 19(1), 74–78 (2006).
- 38 Phillips K, Menard W, Pagano M, Fay C, Stout R: Delusional versus nondelusional body dysmorphic disorder: clinical features and course of illness. *J. Psychiatr. Res.* 40(2), 95–104 (2006).
- 39 Hollander E, Allen A, Kwon J *et al.*: Clomipramine vs desipramine crossover trial in body dysmorphic disorder selective efficacy of a serotonin reuptake inhibitor in imagined ugliness. *Arch. Gen. Psychiatry* 56, 1033–1039 (1999).
- 40 Hanes KR: Neuropsychological performance in body dysmorphic disorder. *J. Int. Neuropsychol. Soc.* 4(2), 167–171 (1998).
- 41 Dunai J, Labuschagne I, Castle D, Kyrios M, Russell S: Executive function in body dysmorphic disorder. *Psychol. Med.* 40(9), 1541–1548 (2010).
- 42 Buhlmann U, McNally RJ, Wilhelm S, Florin I: Selective processing of emotional information in body dysmorphic disorder. *J. Anxiety Disord.* 16(3), 289–298 (2002).
- 43 Deckersbach T, Savage CR, Phillips K *et al.*: Characteristics of memory dysfunction in body dysmorphic disorder. *J. Int. Neuropsychol. Soc.* 6, 673–681 (2000).
- 44 Buhlmann U, McNally RJ, Etcoff NL, Tuschen-Caffier B, Wilhelm S: Emotion recognition deficits in body dysmorphic disorder. *J. Psychiatr. Res.* 38, 201–206 (2004).
- 45 Feusner J, Moller H, Altstein L *et al.*: Inverted face processing in body dysmorphic disorder. *J. Psychiatr. Res.* 44(15), 1088–1094 (2010).
- 46 Feusner J, Townsend J, Bystritsky A, Bookheimer S: Visual information processing of faces in body dysmorphic disorder. *Arch. Gen. Psychiatry* 64, 1417–1426 (2007).
- 47 Van Den Heuvel O, Veltman D, Groenewegen H *et al.*: Disorder-specific neuroanatomical correlates of attentional bias in obsessive–compulsive disorder, panic disorder, and hypochondriasis. *Arch. Gen. Psychiatry* 62, 922–933 (2005).
- 48 Veale D, Sahakian B, Owen A, Marks I: Specific cognitive deficits in tests sensitive to frontal lobe dysfunction in obsessive–compulsive disorder. *Psychol. Med.* 26(06), 1261–1269 (2009).
- 49 Pantelis C, Barnes T, Nelson H *et al.*: Frontal–striatal cognitive deficits in patients with chronic schizophrenia. *Brain* 120(10), 1823–1843 (1997).
- 50 Feusner J, Moller H, Altstein L *et al.*: Inverted face processing in body dysmorphic disorder. *J. Psychiatr. Res.* 44(15), 1088–1094 (2010).
- 51 Boone KB, Ananth J, Philpott L, Kaur A, Djenderedjian A: Neuropsychological characteristics of nondepressed adults with obsessive–compulsive disorder. *Neuropsychiatry Neuropsychol. Behav. Neurol.* 4, 96–109 (1991).

- 52 Savage C, Deckersbach T, Wilhelm S *et al.*: Strategic processing and episodic memory impairment in obsessive–compulsive disorder. *Neuropsychology* 14(1), 141–151 (2000).
- 53 Joshua N, Rossell S: Configural face processing in schizophrenia. *Schizophr. Res.* 112(1), 99–103 (2009).
- 54 Stangier U, Adam-Schwebe S, Muller T, Wolter M: Discrimination of facial appearance stimuli in body dysmorphic disorder. *J. Abnorm. Psychol.* 117(2), 435–443 (2008).
- 55 Reese H, McNally R, Wilhelm S: Facial asymmetry detection in patients with body dysmorphic disorder. *Behav. Res. Ther.* 48(9), 936–940 (2010).
- 56 Buhlmann U, Wilhelm S, McNally RJ, Tuschen-Caffier B, Baer L, Jenike MA: Interpretive biases for ambiguous information in body dysmorphic disorder. *CNS Spectrums* 7(6), 435–436, 441–443 (2002).
- 57 Clerkin EM, Teachman BA: Perceptual and cognitive biases in individuals with body dysmorphic disorder symptoms. *Cogn. Emot.* 22(7), 1327–1339 (2008).
- 58 Feusner J, Bystritsky A, Helleman G, Bookheimer S: Impaired identity recognition of faces with emotional expressions in body dysmorphic disorder. *Psychiatry Res.* 179(3), 318–323 (2010).
- 59 Haxby J, Hoffman E, Gobbini M: The distributed human neural system for face perception. *Trends Cogn. Sci.* 4(6), 223–232 (2000).
- 60 Stein MB, Goldin PR, Sareen J, Zorrilla LT, Brown GG: Increased amygdala activation to angry and contemptuous faces in generalized social phobia. *Arch. Gen. Psychiatry* 59, 1027–1034 (2002).
- 61 Iidaka T, Yamashita K, Kashikura K, Yonekura Y: Spatial frequency of visual image modulates neural responses in the temporo–occipital lobe. An investigation with event-related fMRI. *Brain Res. Cogn. Brain Res.* 18(2), 196–204 (2004).
- 62 Vuilleumier P, Armony J, Driver J, Dolan R: Distinct spatial frequency sensitivities for processing faces and emotional expressions. *Nat. Neurosci.* 6(6), 624–631 (2003).
- 63 Van Kleeck M: Hemispheric differences in global versus local processing of hierarchical visual stimuli by normal subjects: new data and a meta-analysis of previous studies. *Neuropsychologia* 27(9), 1165–1178 (1989).
- 64 Feusner J, Moody T, Hembacher E *et al.*: Abnormalities of visual processing and frontostriatal systems in body dysmorphic disorder. *Arch. Gen. Psychiatry* 67(2), 197–205 (2010).
- 65 Rauch SL: Neuroimaging research and the neurobiology of obsessive–compulsive disorder: where do we go from here? *Biol. Psychiatry* 47(3), 168–170 (2000).
- 66 Feusner J, Moody T, Hembacher E, Hoffman J, Moller H, Bookheimer S: Object visual processing in body dysmorphic disorder. Presented at: *18th European Congress of Psychiatry*. Munich, Germany, 27 February–2 March 2010.
- 67 Carey P, Seedat S, Warwick J, Van Heerden B, Stein DJ: SPECT imaging of body dysmorphic disorder. *J. Neuropsychiatry Clin. Neurosci.* 16(3), 357–359 (2004).
- 68 Trimble M: Body image and the temporal lobes. *Br. J. Psychiatry Suppl.* 2, 12–20 (1988).
- 69 Kanwisher N, McDermott J, Chun M: The fusiform face area: a module in human extrastriate cortex specialized for face perception. *J. Neurosci.* 17, 4302–4311 (1997).
- 70 Buhlmann U, Etcoff NL, Wilhelm S: Emotion recognition bias for contempt and anger in body dysmorphic disorder. *J. Psychiatr. Res.* 40(2), 105–111 (2006).
- 71 Rauch SL, Phillips K, Segal E *et al.*: A preliminary morphometric magnetic resonance imaging study of regional brain volumes in body dysmorphic disorder. *Psychiatry Res.* 122(1), 13–19 (2003).
- 72 Whiteside S, Port J, Abramowitz J: A meta-analysis of functional neuroimaging in obsessive–compulsive disorder. *Psychiatry Res.* 132(1), 69–79 (2004).
- 73 Atmaca M, Bingol I, Aydin A *et al.*: Brain morphology of patients with body dysmorphic disorder. *J. Affect. Disord.* 123(1–3), 258–263 (2010).
- 74 Saxena S, Bota R, Brody A: Brain–behavior relationships in obsessive–compulsive disorder. *Semin. Clin. Neuropsychiatry* 6(2), 82–101 (2001).
- 75 Rotge: Gray matter alterations in obsessive–compulsive disorder: an anatomic likelihood estimation meta-analysis. *Biol. Psychiatry* 35(3), 686–691 (2010).
- 76 Feusner J, Townsend J, Bystritsky A *et al.*: Regional brain volumes and symptom severity in body dysmorphic disorder. *Psychiatry Res.* 172(2), 161–167 (2009).
- 77 Rauch S, Savage C, Alpert N, Fischman A, Jenike M: The functional neuroanatomy of anxiety: a study of three disorders using positron emission tomography and symptom provocation. *Biol. Psychiatry* 42(6), 446–452 (1997).
- 78 Phelps E: Human emotion and memory: interactions of the amygdala and hippocampal complex. *Curr. Opin. Neurobiol.* 14(2), 198–202 (2004).
- 79 Buhlmann U, Cook LM, Fama JM, Wilhelm S: Perceived teasing experiences in body dysmorphic disorder. *Body Image* 4, 381–385 (2007).
- 80 Neziroglu F, Khemlani-Patel S, Veale D: Social learning theory and cognitive behavioral models of body dysmorphic disorder. 5(1), 28–38 (2008).
- Gives an account of social learning and cognitive behavioral models of BDD. While the current review has focused on the neurobiological aspects of BDD there is also a developing and important literature on the psychological underpinnings of the disorder.
- 81 Veale D: Advances in a cognitive behavioural model of body dysmorphic disorder. *Body Image* 1(1), 113–125 (2004).
- 82 Bienvenu O, Samuels JF, Riddle MA *et al.*: The relationship of obsessive–compulsive disorder to possible spectrum disorders: results from a family study. *Biol. Psychiatry* 48(4), 287–293 (2000).
- Website
- 101 Diagnostic and Statistical Manual of Mental Disorders V www.dsm.org (Accessed 7 July 2010)